

OCULAR HISTOPLASMOSIS IN IMMUNIZED AND IMMUNOSUPPRESSED RABBITS

Robert A. Fromtling, Marion E. Woolsey, and Marcel Binstock*

Faculty of Natural Sciences, University of Tulsa, Tulsa, Oklahoma

Clinical evidence suggests that macular disease may occasionally be a result of infection by *Histoplasma capsulatum*. Experiments were performed to study the induction of ocular lesions by this fungus. A group of Dutch Belted rabbits was immunized with killed mycelial antigen, rested, and then challenged with live yeast antigen. Another group of rabbits was treated with cyclophosphamide and infected with live yeast antigen. Results indicate that prior immunization does not prevent occurrence of ocular lesions, and that cyclophosphamide-treated rabbits, as expected, produced more numerous ocular lesions of greater duration. Although prior immunization apparently does not afford protection against ocular infection, these studies support the hypothesis that severity of ocular lesions and immuno-incompetency are positively related.

INTRODUCTION

Clinical evidence indicates that macular disease may occasionally be a result of infection by the dimorphic, systemic fungus *Histoplasma capsulatum* (1, 2). The syndrome known as presumed ocular histoplasmosis is a form of ocular choroiditis characterized by serous and hemorrhagic detachment of the macula associated with characteristic multiple peripheral choroidal lesions, and occasionally peripapillary choroiditis.

Recent evidence by several investigators (3, 4, 5) has indicated a relationship between histoplasmosis infection and ocular disease. Using the fluorescent antibody technique, Smith and his associates (3) detected cell walls of *H. capsulatum* in active choroidal foci of granulomatous inflammation. However, they could not find *H. capsulatum* in the inactive lesions examined several weeks after the onset of the acute infection.

Day (6) was the first to report that immunization with *H. capsulatum* spores imparts ocular resistance to later infection with living organisms. This was supported by Wong (5), who showed that New Zealand white rabbits immunized with killed *H. capsulatum* did not develop uveitis when subsequently challenged with living organisms.

Cyclophosphamide (Cytoxan[®], CY) is a strong alkylating agent with an ability to suppress the humoral immune system and, to a lesser extent, the cellular immune system (7, 8, 9, 10).

Cozad and Lindsey (10) tested the effect of cyclophosphamide on *H. capsulatum* infections in mice. They noted a greater susceptibility to and severity of systemic disease and a five-fold increase in the numbers of organisms isolated from the spleens of CY-treated mice, as compared with non-drug-treated animals.

The purposes of our investigations were: (a) to further test the ability of killed mycelial-phase *H. capsulatum* to protect an animal from later active infection, and (b) to determine if a correlation exists between occurrence and severity of chorioretinal lesions and the immunocompetence of rabbits.

MATERIALS AND METHODS

Animals.

Six-to-nine-month-old Dutch Belted rabbits (Ancare Corp., Manhasset, N.Y.) of mixed sexes were used in our experimental studies. Purina laboratory chow and water were provided *ad libitum*.

Organism.

The Scritchfield strain of *Histoplasma capsulatum* was provided by Dr. Howard Larsh of The University of Oklahoma, Norman, Oklahoma. The mycelial phase was maintained on Sabouraud dextrose agar (Difco), the yeast phase on cysteine-heart agar enriched with 1% Bacto-hemoglobin (B136; Difco).

*Present address: Tulsa Retina Clinic, Hillcrest Medical Center, Tulsa, Oklahoma 74104

Inoculum.

To prepare the killed mycelial inoculum, *H. capsulatum* was grown on Sabouraud dextrose agar slants at 25 C for 14 days. The cultures were washed from the agar and suspended in 0.5% formalin-saline until all organisms were dead, as determined by no growth on subcultures. Live inoculum was grown on hemoglobin-enriched cysteine-heart agar slants at 37 C for 60 hours. Growth was removed with sterile 0.9% saline. Both viable and killed organisms were washed four times and resuspended in sterile saline for inoculation. The suspensions were counted for mycelial fragments or yeast cells in a standard Neubauer hemocytometer. Purity and percent viability of the live yeast suspension were determined by culturing an aliquot of the washed suspension, and an average of 72% viability was obtained.

CY dosage.

Twenty-five milligrams of cyclophosphamide (Mead-Johnson) per kilogram of animal weight were injected intraperitoneally on five consecutive days as a freshly made saline solution containing 20 mg CY/ml saline.

Examination of animals.

Animal pupils were dilated with Murocoll: 10% phenylephrine hydrochloride and 0.3% scopolamine hydrobromide (Muro Pharmacal Laboratories, Inc., Quincy, Mass.). Fundus examinations were performed with an indirect ophthalmoscope (Xonic, Inc., Waltham, Mass.) prior to treatment or infection and all abnormalities were recorded. Post-treatment and post-infection examinations were performed and all ocular lesions were recorded.

Immunization of animals.

Rabbits were given six weekly injections via the marginal ear vein of 2×10^8 killed mycelial fragments per kilogram of body weight. The animals were rested for 13 months and then challenged intravenously with 4×10^8 live yeast cells per kilogram body weight. Periodic bleedings from the marginal ear vein and ocular examinations were performed throughout the experimental period. Control animals received normal saline injections intravenously.

Immunosuppression and infection of animals.

Rabbits were treated with CY as previously described. On day two the animals were infected intravenously with 2.25×10^6 live yeast cells per kilogram of body weight. The animals were observed over a 30-day period. Changes in animal weights and white blood cell counts were recorded on alternate days. Periodic bleedings from the marginal ear vein and ocular examinations were performed. One group of control animals (CY control) received CY treatment and no fungus infection; a second group of control animals (*H. capsulatum* control) received normal saline treatment in place of CY and were infected with fungus.

Immunological analysis.

Skin tests were performed by intradermal injection of 0.1 ml of a 1:100 dilution of the Scritchfield skin test antigen (prepared in the laboratory of Dr. Howard Larsh, University of Oklahoma). Skin tests were performed prior to *H. capsulatum* infection and at intervals following inoculation.

Immunodiffusion in agar gel was used to detect precipitating antibodies against *H. capsulatum*. Collected sera were tested against a commercial preparation of histoplasmin (CDC Lot No. H-42-68) skin test antigen diluted 1:25 as outlined by NCDC (11).

TABLE 1. Rabbits immunized with killed mycelial-phase *H. capsulatum*.

Rabbit	Inoculum	Dosage (orga- nisms/kg)	Route	Immuno- diffusion max. titer	Skin test	Retinal lesions	
						Left	Right
Control	0.9% Saline	Equivalent volume	i.v.	0	—	0	0
1	Killed mycelium	2×10^8	i.v.	1:8	+	0	0
2	Killed mycelium	2×10^8	i.v.	1:16	+	0	0
3	Killed mycelium	2×10^8	i.v.	1:16	+	0	0

RESULTS

Results of experiments designed to test the protection afforded by immunization with killed mycelial phase *H. capsulatum* are summarized in Table 1 and Table 2. During the immunizing phase of the experiment, skin tests became positive about 18 days post initial immunization, and maximum immunodiffusion titers of 1:16 were obtained. No chorioretinal lesions were observed in any of the animals.

Following a 13-month resting period and subsequent challenge with live organisms, all animals showed minor signs of infection, including decreased intake of water and food and respiratory congestion, for two weeks post challenge. Skin test reactions were exacerbated and a maximum immunodiffusion titer of 1:2 was obtained. Fundus examinations disclosed numerous chorioretinal lesions in two of the three experimental rabbits.

Results of experiments designed to determine if a correlation exists between immunocompetence and the occurrence of chorioretinal lesions are summarized in Table 3. Changes in animal weights (Figure 1) and in white blood cell counts (Figure 2) are expressed as z-scores, which are standard deviations from the mean. The expressed mean is that of all animals throughout the entire 30-day experimental period.

Decreases in weight were observed for control and experimental animals in response to the CY treatment. While the weights of the CY control group returned to normal within 22 days post initiation of treatment, *the weights of the animals infected with H. capsulatum (control and experimental) remained below mean level and did not return to the original value during the 30-day observational period.*

Decreases in white blood cell count were noted for the CY-treated groups. Within 15 days post initiation of treatment, the WBC counts had returned to normal in the control group. The experimental animals displayed an initial decrease in WBC count followed by an increase above normal levels with a return to original values at about 22 days. However, following infection, the *H. capsulatum* control group displayed only an increase in WBC count which persisted for about 20 days before returning to normal.

Examination of the data obtained from control and experimental rabbits shows that the CY control group remained skin test negative to Scritchfield histoplasmin and produced no detectable precipitating antibodies against H-42 histoplasmin. No chorioretinal lesions were observed in any of the members of this group. The *H. capsulatum* control group became skin test positive 18 days post infection and displayed a maximum immunodiffusion titer of 1:8. An average of nine chorioretinal lesions were observed per rabbit with the lesions first appearing 12 days post infection. Once observed, ocular lesions in this group had a maximum duration of 24 days. The experimental group became skin test positive 23 days post infection and a maximum immunodiffusion titer of 1:2 resulted. An average of 16 chorioretinal lesions were observed per rabbit; these first appeared eight days post infection. Many of the lesions were still clearly visible 45 days after first appearance.

DISCUSSION

In Dutch Belted rabbits immunization with killed mycelial-phase *H. capsulatum* does not parallel the findings of Wong (5), on New Zealand white rabbits, that protec-

TABLE 2. Rabbits immunized with killed mycelial-phase *H. capsulatum* challenged 13 months later with live yeast-phase *H. capsulatum*.

Rabbit	Inoculum	Dosage (orga- nisms/kg)	Route	Immuno- diffusion max. titer	Skin test	Retinal lesions	
						Left	Right
Control	0.9% Saline	Equivalent volume	i.v.	0	—	0	0
1	Live yeast	4×10^8	i.v.	1:2	+	0	0
2	Live yeast	4×10^8	i.v.	1:2	+	16	14
3	Live yeast	4×10^8	i.v.	1:2	+	12	2

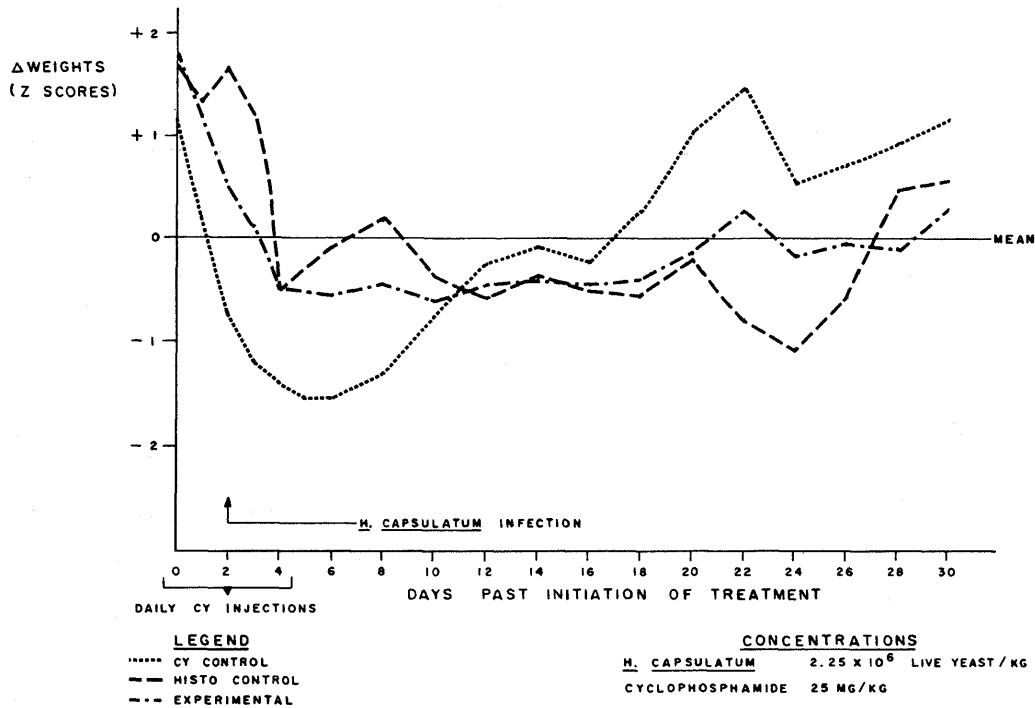


FIGURE 1. Changes in animal weights of control and experimental rabbits.

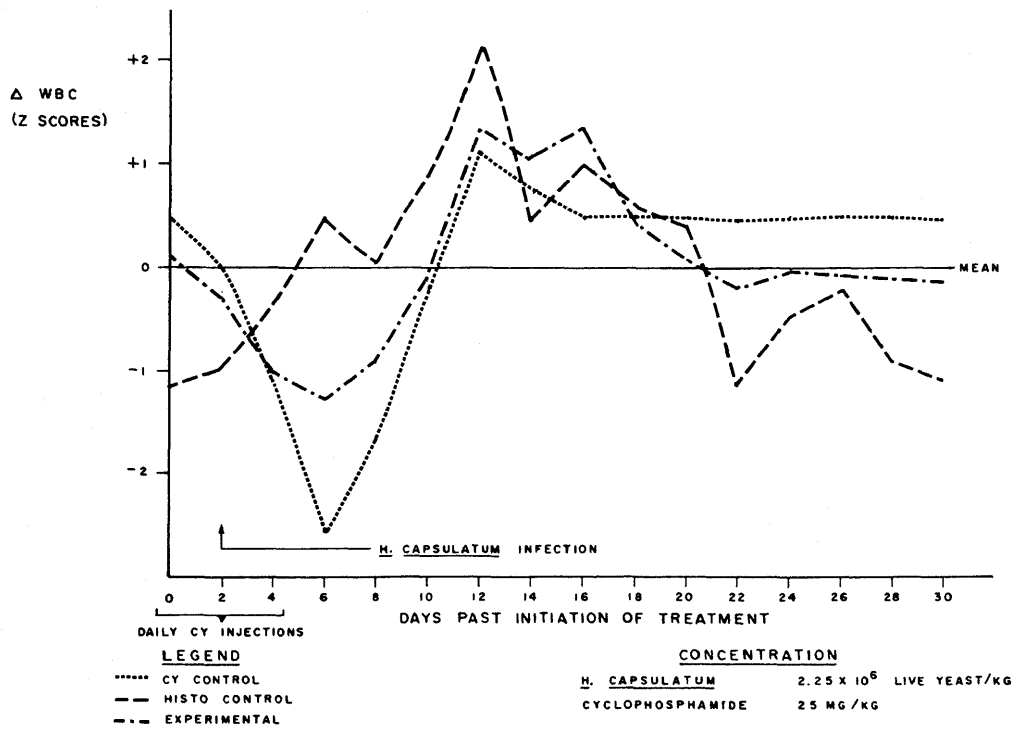


FIGURE 2. Changes in white cell counts of control and experimental rabbits.

TABLE 3. Summary of data on control and experimental rabbits.

Rabbits	Inoculum	CY dosage (mg/kg)	<i>H. cap.</i> Conc/kg	Immuno- diffusion max. titer	(+) Skin Test Days Elapsed	Mean chorioretinal lesions		
						Number observed Left	Right	Days past infection 1st seen
CY control	--	25	--	0	0	0	0	0
<i>H. capsulatum</i> control	Live yeast	--	2.25×10^6	1:8	18	4	5	12
Experimental	Live yeast	25	2.25×10^6	1:2	23	9	8	≥ 45

tion from active infection was seen in animals immunized with dead organisms. The occurrence of ocular lesions in two of the three immunized animals in this study indicates that prior immunization with killed mycelia generally may not prevent the formation of ocular lesions. The apparent absence of an anamnestic response in immune animals when challenged with live organisms has been previously noted (12). We feel that further investigation will be needed to make a valid interpretation of this result.

The experimental studies using cyclophosphamide clearly showed a decrease in animal weight and white blood cell count in response to CY treatment. As previously reported (7, 8, 9, 10), marked suppression of the humoral immune response as well as some suppression of the cellular immune response was noted. The occurrence of ocular lesions was noted in all experimental animals. The number of chorioretinal lesions in infected rabbits treated with CY when compared to rabbits not treated with CY increased by 89%. The ocular lesions first appeared four days earlier and persisted at least 21 days longer in the experimental group than in the *H. capsulatum* control group.

This investigation indicates that immunosuppression results in an earlier occurrence, greater number, and longer duration of chorioretinal lesions in rabbits. We feel that the lesions persisting for more than 45 days may lead to permanent scarring which may be comparable to the peripheral scarring seen in human patients. Further studies on the effect of immunosuppression with antilymphocyte serum, which most markedly depresses the cellular immune response, are planned to determine the possible relationship between cellular immunity and the occurrence and severity of ocular lesions.

ACKNOWLEDGMENTS

The authors wish to express their gratitude to Dr. Ted W. Nickel, Department of Psychology, University of Tulsa, for his statistical suggestions and writing of a Compucorp program used in this study, and to R. H. Fromtling for his preparation of the figures.

They also wish to thank Anne M. Kovacs for her capable technical assistance.

Partial support of these studies was provided by Research Corporation, New York, the Helmerich Foundation, Tulsa, Oklahoma, and the University of Tulsa student research program, Grant No. R-3300-53.

Robert A. Fromtling was supported by an F. B. Parriott Graduate Scholarship for the duration of this work.

REFERENCES

1. R. E. SMITH, G. R. O'CONNOR, C. J. HALDE, M. A. SCALARONE, and W. M. EASTERBROOK, *Am. J. Ophthalmol.* 76: 284-93 (1973).
2. A. C. WOODS and H. E. WHALEN, *Trans. Am. Ophthalmol. Soc.* 57: 318-43 (1959).
3. R. E. SMITH, M. A. SCALARONE, G. R. O'CONNOR, and C. J. HALDE, *Am. J. Ophthalmol.* 76:375-80 (1973).
4. M. E. WOOLSEY, M. BINSTOCK, and M. J. McDONALD, *Proc. Okla. Acad. Sci.* 54: 44-7 (1974).
5. V. G. WONG, *Trans. Am. Ophthalmol. Soc.* 70: 615-30 (1972).
6. R. DAY, *Am. J. Ophthalmol.* 32: 1317-30 (1949).
7. M. FOX, *Transplantation* 2: 475-86 (1964).
8. A. WINKELSTEIN, J. M. MIKULLA, H. R. NANKIN, B. H. POLLACK, and B. L. STOLZER, *J. Lab. Clin. Med.* 80: 506-13 (1972).
9. R. G. DEVLIN, N. J. SCHWARTZ, H. K. MACKEY, and P. E. BARONOWSKY, *Transplantation* 17: 70-4 (1974).
10. G. C. COZAD and T. J. LINDSEY, *Infect. Immun.* 9: 261-5 (1974).
11. *Laboratory Diagnosis by Serologic Methods*, Instruction Manual for CDC Course #9440-C, National Center for Disease Control, Chamblee, Ga., pp. 3-7.
12. M. J. McDONALD, *Experimental Ocular Histoplasmosis*, M.S. thesis, University of Tulsa, Tulsa, Oklahoma, 1975.